

The Axillary nerve branches off the posterior cord. It runs posterior to the neck of the humerus and innervates the deltoid and teres minor muscles and the skin and joint capsul of the shoulder.

Postganglionic fibers emerging from the middle and inferior cervical ganglia enter cervical nerves C4-C8. Some of these fibers innervate the heart, but most serve the skin (The inferior cervical ganglion is also called the Stellate ganglion because of its star-like shape) (At C7)

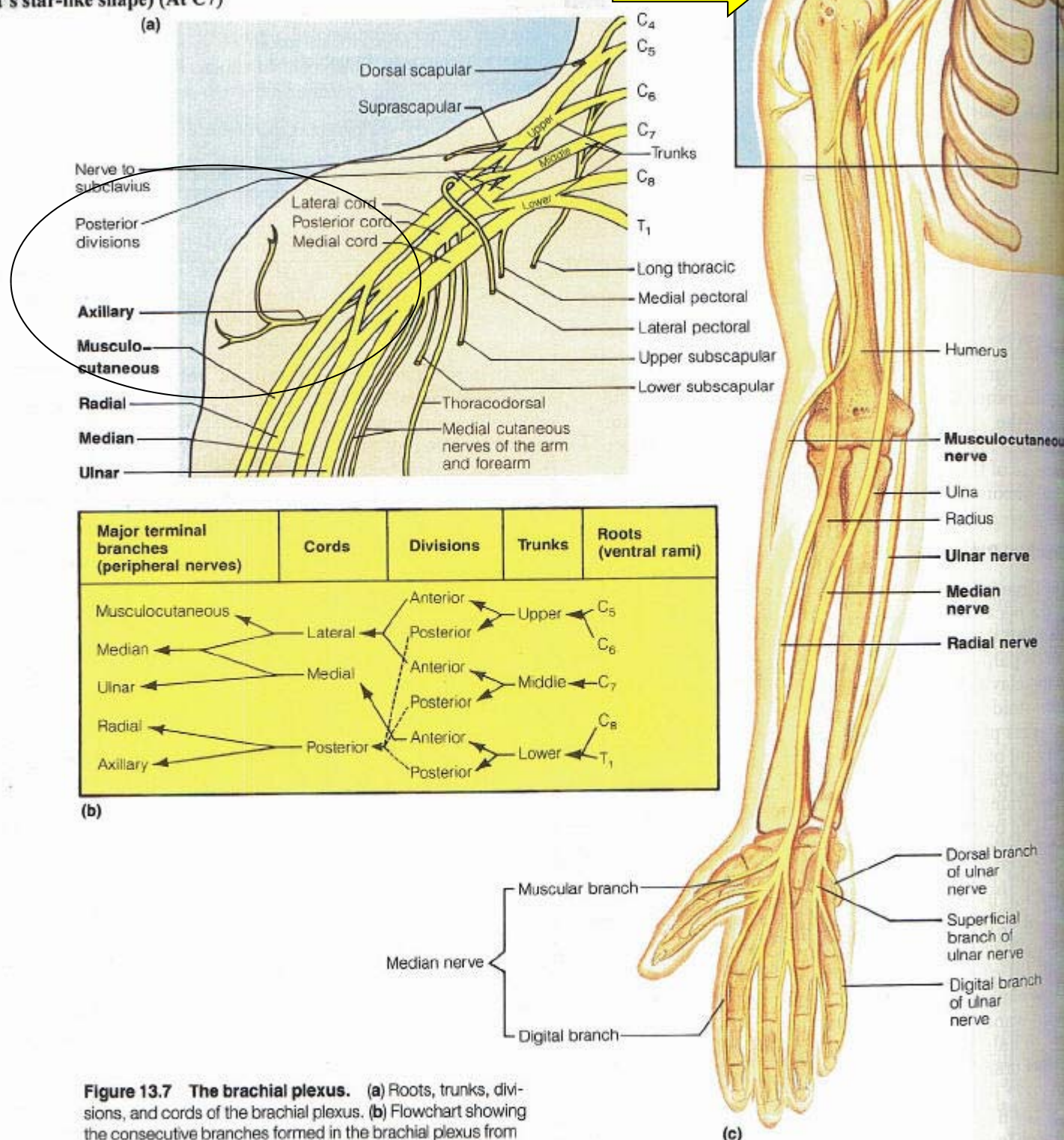


Figure 13.7 The brachial plexus. (a) Roots, trunks, divisions, and cords of the brachial plexus. (b) Flowchart showing the consecutive branches formed in the brachial plexus from the spinal roots (ventral rami) to the major nerves formed from the cords. (c) Distribution of the major peripheral nerves of the upper limb. (See Table 13.4.)